

**PATIENT**

Milo Manzano

**SPECIES**

Canine

**BREED**

Cockapoo

**SEX**

Male Neutered

**AGE**

13 years

**WEIGHT**

22lbs

**INTERPRETED BY**

Maggie Machen Lamy,  
DVM, DACVIM  
(Cardiology)

**IMAGING PERFORMED BY**

Kelly Vazquez, CVT

**HOSPITAL NAME**

Animal General on  
Hudson

**REFERRING VET**

Dr. Zelinski

**INVOICE**

24013

**DATE**

5/4/22

**PRESENTING CLINICAL SIGNS**

History: Recheck echo. Asses prior to anesthesia. Current medications: Apoquel.  
-Pertinent previous echo findings (10/2020 MML): Mild to moderate MR, no LA or LVE, mild systolic dysfunction, FS: 27%, trace TR: 2.6m/s, LA: 1.4, LV: 3.3.

**ECHOCARDIOGRAM FINDINGS**

2D, m-mode, color flow and doppler imaging is available. Diffuse thickening of mitral valve leaflets with mild prolapse into the left atrial lumen. Moderate eccentric mitral regurgitation with moderate left atrial dilation. Normal MR velocity. Borderline LV diameter with adequate myocardial function. The tricuspid valve appears normal with trace tricuspid regurgitation. Normal velocity. Normal right atrial and ventricular diameter and morphology indicating no overt evidence of pulmonary arterial hypertension. The pulmonic and aortic valves are normal in morphology and mobility. Normal pulmonic and aortic outflow velocities with laminar flow. No aortic or pulmonic insufficiency. No pericardial or pleural effusion noted. No obvious cardiac masses.

**CARDIAC CHART**

CANINE CARDIAC PARAMETERS	MR VMAX (m/s)	TR VMAX (m/s)	LA/AO (Boon method)	LA/AO (Heart Base; Swe)	FS (%)	EF (%)	EPSS (cm)
NORMAL PARAMETER	4.5-5.5	<2.7	1.3	<1.6	28-40	40-100	<0.6
PATIENT	6.0	2.2	1.5	1.67	37	70	0.55
CANINE CARDIAC PARAMETERS	HR (BPM)	AV VMAX (m/s)	PV MAX (m/s)	BODY WEIGHT (kg)	LA 2D short axis Base view (cm)	LVIDd Avg; 2D and m-mode short axis (cm)	LVIDs Avg; 2D and m-mode short axis (cm)
NORMAL PARAMETER	50-100	0.7-1.7	0.7-1.6	BELOW	BELOW	BELOW	BELOW
PATIENT	100	1.1	0.84	10.0	2.0	3.5	2.2
*Normal chamber parameters expressed as a mean value (SD)				3	1.27 (5.3)	2.46 (2.46)	1.36 (5.5)
<b>BODY WEIGHT DEPENDENT PARAMETERS</b>				5	1.40 (4.5)	2.74 (5.2)	1.60 (4.7)
<i>*Note: All measurements based upon multi-modal images and methods. An average value is reported.</i>				10	1.50 (3.8)	3.27 (3.5)	2.06 (3.1)
				15	1.83 (2.0)	3.71 (2.4)	2.43 (2.1)
				20	2.02 (1.9)	4.14 (2.2)	2.80 (2.0)
				25	2.18 (2.4)	4.48 (2.9)	3.10 (2.5)
				30	2.33 (3.3)	4.83 (3.9)	3.39 (3.4)
				35	2.48 (4.3)	5.17 (5.0)	3.69 (4.5)
				40	2.62 (5.2)	5.48 (6.1)	3.96 (5.4)
				50	2.88 (7.1)	6.07 (8.3)	4.46 (7.4)

Adapted from June Boon, Veterinary Echocardiography, 1998  
Rishniw M and Hollis NE, J Vet Intern Med 2000; 14:429-435  
Hansson et al, Vet Rad and Ultrasound 2002  
Bonagura et al. Echocardiography: principles of interpretation, Vet Clin North Am 15:1177, 1995

**INTERPRETATION OF THE FINDINGS & FURTHER RECOMMENDATIONS**

Chronic degenerative valve disease persists with evidence of mild progression. The LA and LV dimensions are mildly increased comparatively, with a slight increase in MR quantity. Trace TR is unchanged without obvious evidence of pulmonary hypertension. Finally, previous noted systolic dysfunction is not apparent on this exam. No additional issues are identified.



**PATIENT**

Milo Manzano

Given these findings, Pimobendan is now indicated in this patient as below. This may be a conservative approach given the findings; however, recommend err on the side of caution. Assessment of progression in the future will help predict long term outcome, however prognosis is guarded at this stage (B2).

**SPECIES**

Canine

Omega fatty acid supplementation and mild salt restriction may also be of some long-term benefit. Monitor for development of a progressive cough, labored breathing, exercise intolerance or collapse episodes.

**BREED**

Cockapoo

Once on the medication for 3-5 days, anesthetic risk is considered mildly elevated. Cardiac protective drug choices (opioid/benzodiazepine premedication, Propofol or alfaxalone induction, iso or sevo gas) are recommended. Monitor for arrhythmias, hypotension, and hypoxia both intra and post-operatively and intervene as necessary. Judicious IV fluid rates are recommended to avoid fluid overload. Avoid heart rate stimulating drugs such as atropine unless clinically indicated.

**SEX**

Male Neutered

**AGE**

13 years

**PLAN**

Baseline BP recommended. Institute heart muscle support Pimobendan 0.25-0.3mg/kg PO q12h.

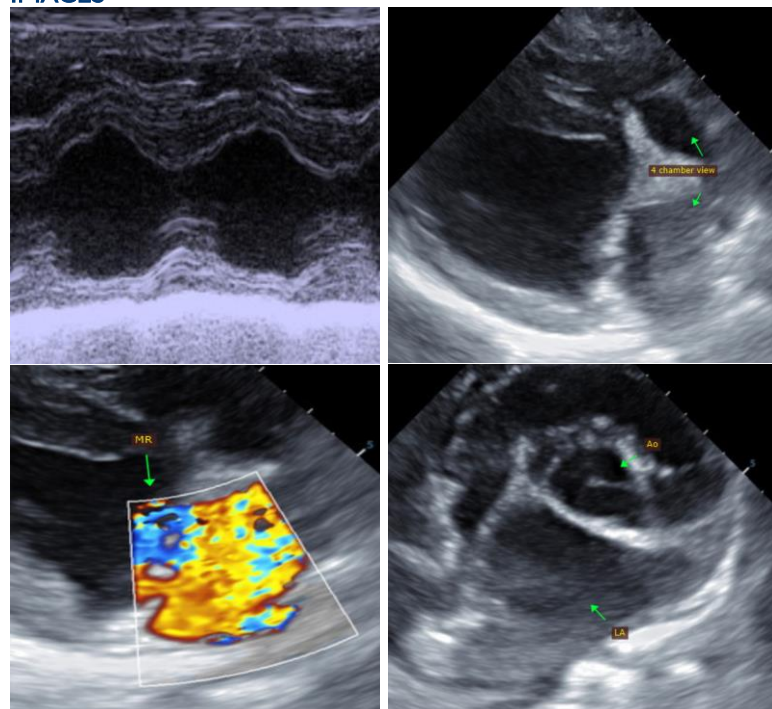
**WEIGHT**

22lbs

Recommend monitor for progression with a recheck echocardiogram in 6 months, sooner if any development of clinical signs.

**INTERPRETED BY**

Maggie Machen Lamy,  
DVM, DACVIM  
(Cardiology)



**IMAGING PERFORMED BY**

Kelly Vazquez, CVT

**HOSPITAL NAME**

Animal General on Hudson

**REFERRING VET**

Dr. Zelinski

**INVOICE**

24013

**DATE**

5/4/22



**PATIENT**

Milo Manzano

The information and recommendations provided are based on the images presented by the referring veterinarian. No evaluation can be communicated regarding pathology that was not visible in the image/video clips provided.

**SPECIES**

Canine

Thank you for this referral. This report was generated using transcription software, and minor dictation errors may be present. If the clinical or image interpretation does not parallel your findings or if I can be of any further assistance, please contact me.

**BREED**

Cockapoo

Maggie Machen Lamy, DVM  
Diplomate of the American College of Veterinary Internal Medicine (Cardiology)  
info@sonopath.com

**SEX**

Male Neutered

**AGE**

13 years

**WEIGHT**

22lbs

**INTERPRETED BY**

Maggie Machen Lamy,  
DVM, DACVIM  
(Cardiology)

**IMAGING  
PERFORMED BY**

Kelly Vazquez, CVT

**HOSPITAL NAME**

Animal General on  
Hudson

**REFERRING VET**

Dr. Zelinski

**INVOICE**

24013

**DATE**

5/4/22